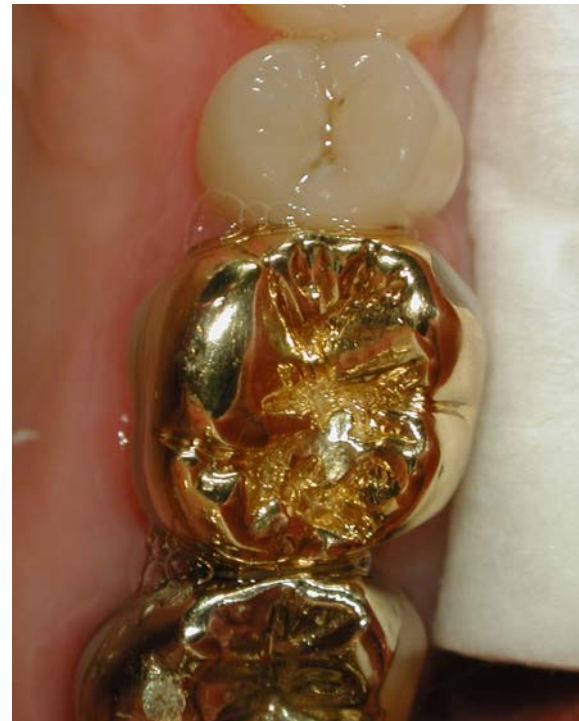
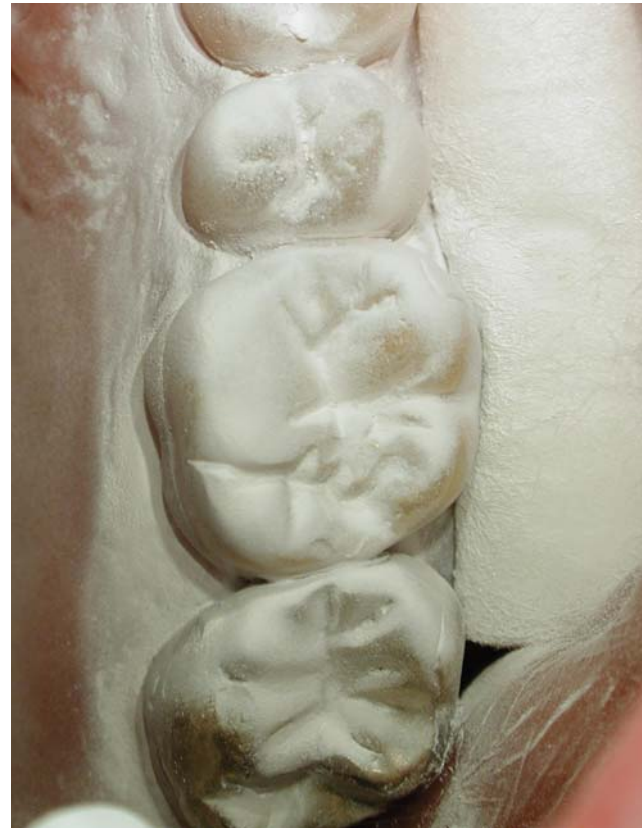
# Upper right first molar with gold restoration, deep caries distal

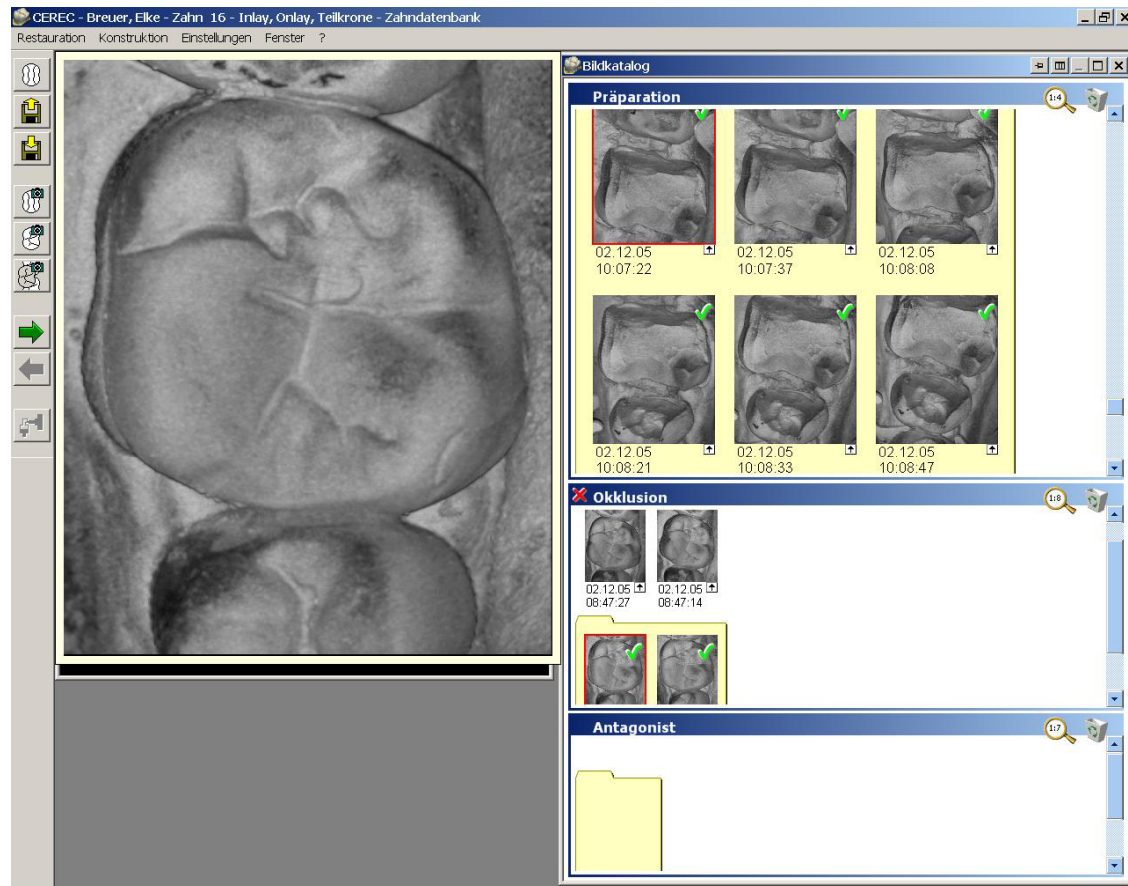

Would you expect a deep caries distal 15? Endo was necessary.

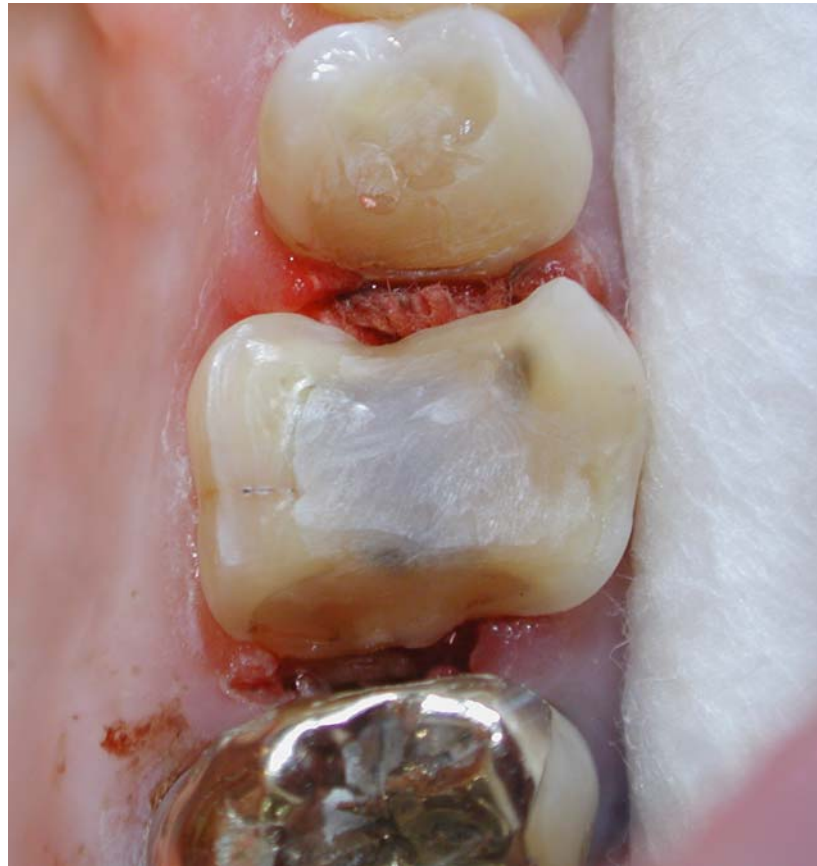# Powdering the occlusion



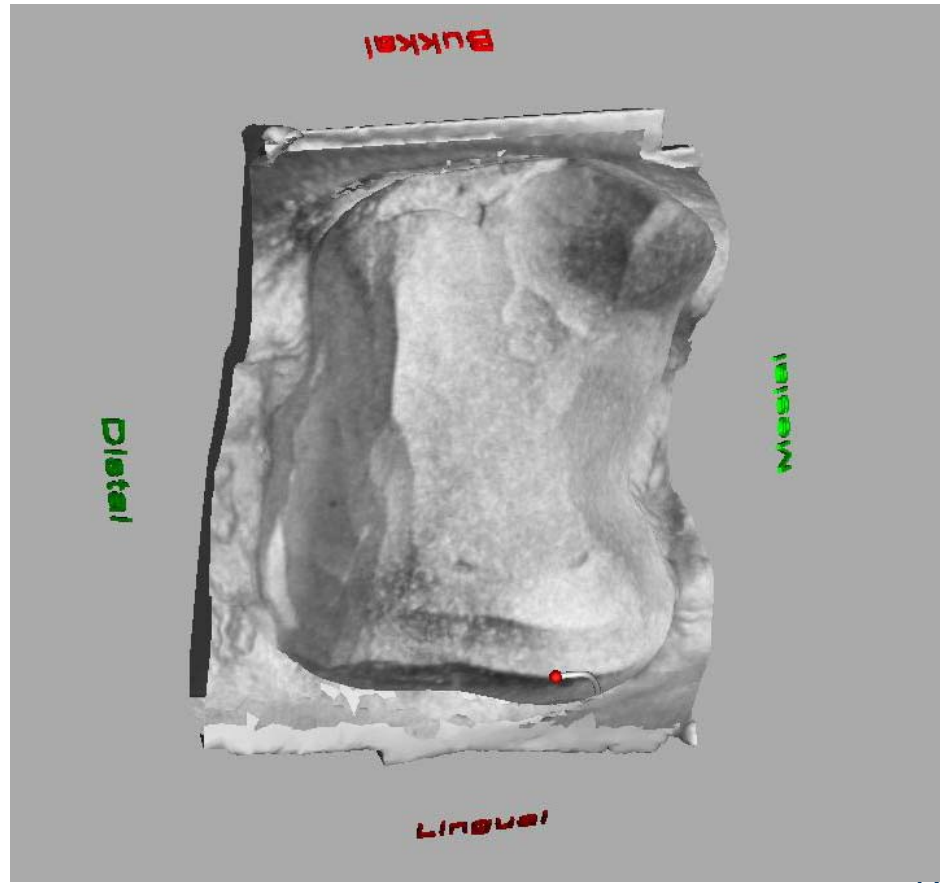
# Powdering of the occlusion - screenshot



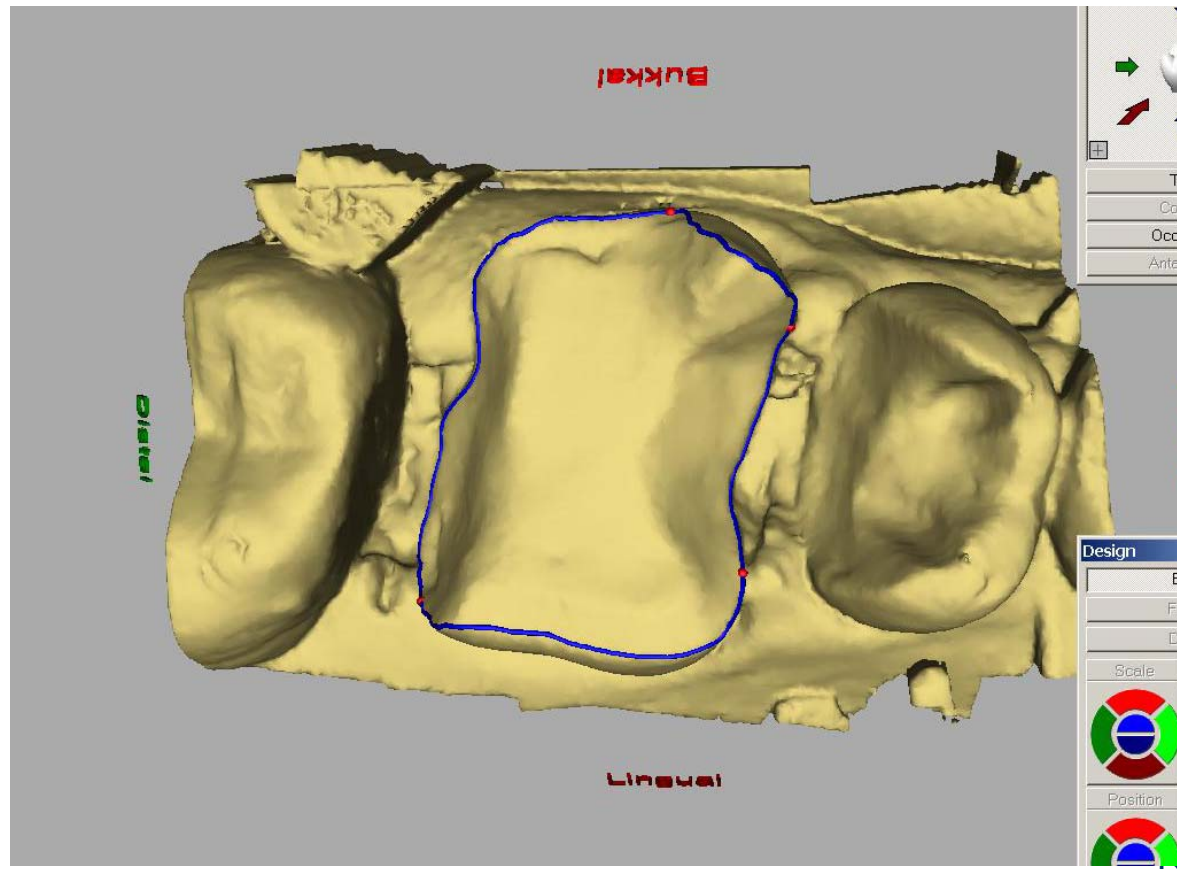
# Transforming the metal restoration design to cerec bath tub design, Endo was done on 15



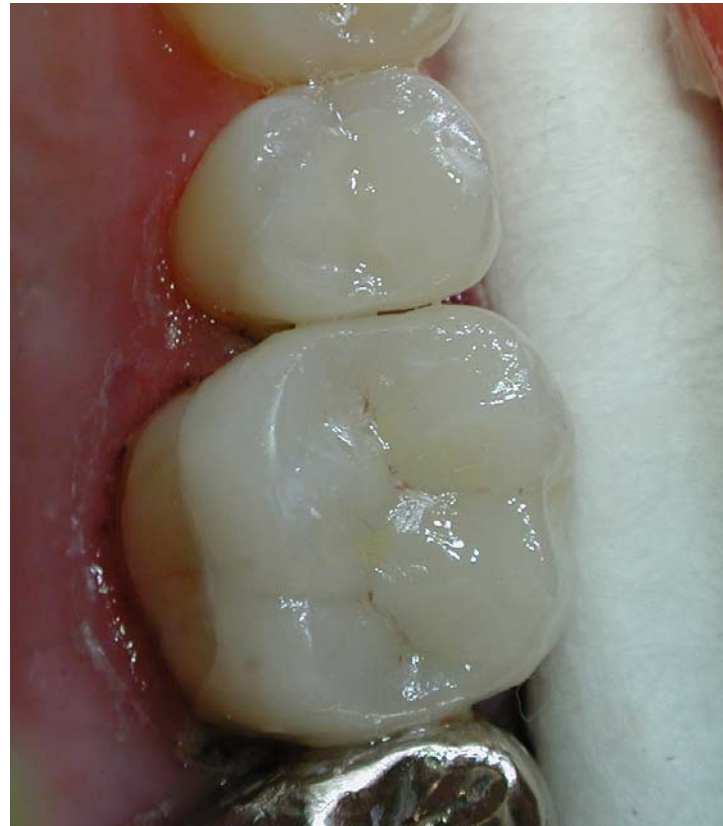**Powdering very thin, but worked well, initial fit was super**



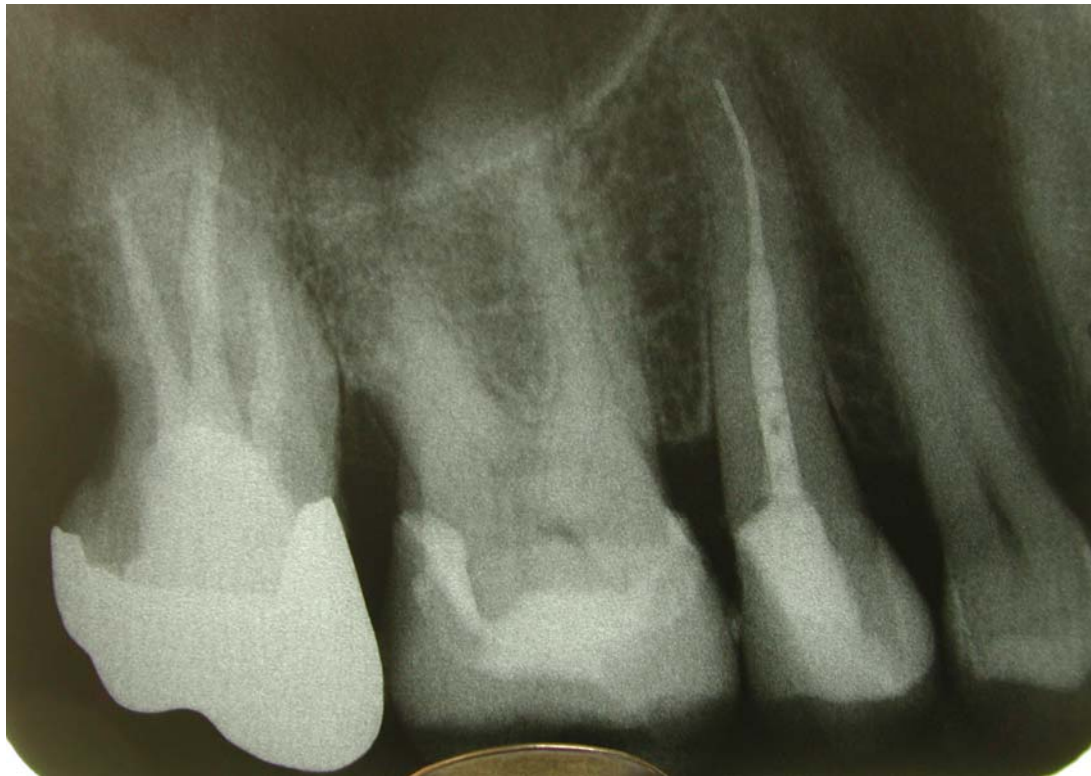# Bath tub design



# After cementation



**End of the morning, Endo on upper second molar and crown had been done in 2000**



# A patient must be tough for cerec

- All this was done during one morning session, while I've treated ten other patients. Powdering was done by my assistant, computer job and lab work was done by one of my dental technicians.
- Next time the first premolar bath tub design shouldn't be that flat, there was no box
- Some of my favourite tricks: adhesive composite underfilling with clearfil photocore, composite compules prewarmed in the hydro bath for cementation, Patient could have left practice without a temporary – til tomorrow